

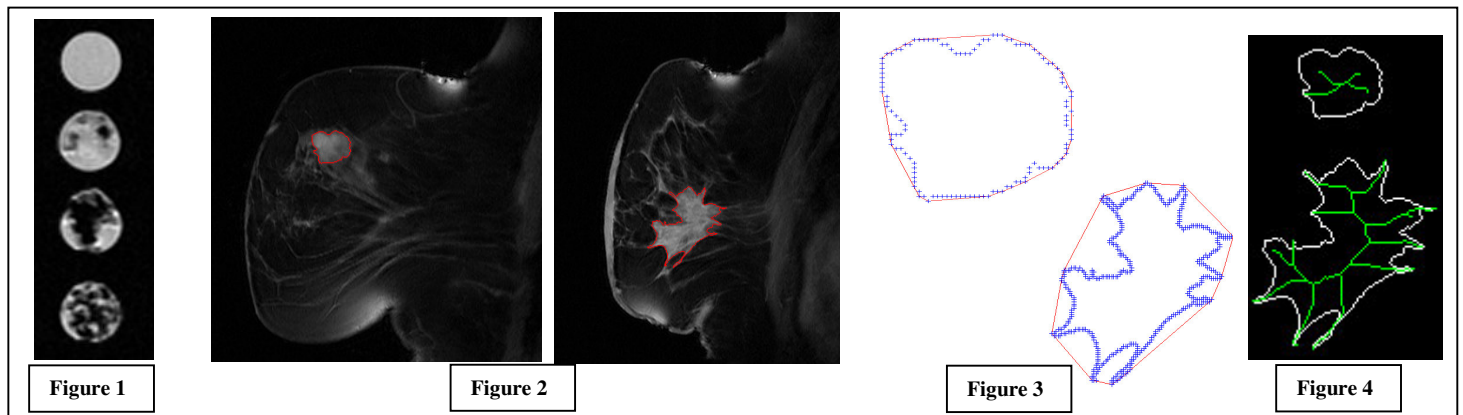
Introduction: MRI has a very high sensitivity for breast lesion detection and has established a role in equivocal findings from conventional mammography techniques. Dynamic contrast enhanced (DCE) data is often used to improve the specificity of the technique by examining enhancement kinetics. If focal enhancement is present then, post-contrast high-resolution imaging is required to visualise important morphological information. Typically a malignant tumour will have an irregular shape and border while a benign mass appears more round [1]. The drawback to this strategy is the large volume of image data produced, the time-intensive analysis required and the inter-observer variability. We have previously examined the efficacy of using semi-automated analysis of DCE data [2]. This work describes the use of lesion shape analysis software to provide morphological features and compares results from both manually drawn and semi-automated regions-of-interest (ROI).

Method: All imaging was performed on a 1.5 Tesla GE Signa scanner operating with a commercially available phased-array breast coil. Localising images were followed by a standard DCE imaging sequence. This was subsequently followed by a high-resolution sequence to demonstrate tumour morphology. This comprised of fat suppressed 3D FSPGR images with a TE/TR/flip = 4.2/20.4 ms/30°, acquired in either the coronal or sagittal plane with in-plane resolutions of 0.15-0.44 mm² and a slice thickness of 3.5-5.0 mm. A total of 47 lesions (34 malignant, 13 benign) were examined.

A computer program was developed in-house using MATLAB (The MathWorks, Inc). Images in DICOM format were directly transferred from the scanner onto the PC. In each case, the slice demonstrating the maximum diameter of the enhancing mass was used for further analysis. A manual ROI was drawn around the circumference of the lesion. In addition a semi-automated method was used to obtain a second ROI. In this case a pixel intensity threshold was used to select enhancing segments of the image, interrogated by the user. The software permitted the editing of this ROI at any stage including manually filling, editing and/or removing pixels or repeating the process.

For both ROIs the area and perimeter were determined (the latter using a 4 pixel neighbour connectivity as default), and the following shape descriptors were measured. The convexity was calculated from the surface of minimum area with convex (outward-bowing) curvature that connected the border pixels, and expressed as the percentage of the convex hull occupied by the original ROI. The circularity was measured as the ratio of the standard deviation to the mean value of the distance of the border pixels from the centre of the ROI, values of zero indicating a circle. Complexity was expressed as the square of the perimeter divided by the area. Finally, elongatedness was measured as the area divided by 4n² where n is the number of iterations of a thinning algorithm, required to remove pixels to form an object with a minimally connected stroke.

In tandem with the clinical study, a simple phantom was constructed to examine shape variation over a wide range using small water-filled tubes with increasing amounts of sponge padding inserted.



Results: Figure 1 shows images in the phantom reproducing a range of in vivo values for circularity, complexity, and elongatedness (0.02-0.32, 9.4-111.1 and 0.87-7.74 respectively). Malignant lesions were characterised by lower convexity, greater complexity, and higher values for circularity and elongatedness than benign lesions. Figure 2 shows semi-automated ROIs in a benign (left) and malignant lesion (right), with a complexity of 12.9 and 47.2 respectively. Figure 3 shows the convex hull (in red) enclosing the perimeters (in blue) for each lesion, with a convexity of 98% (top, benign) and 65% (bottom, malignant). Figure 4 illustrates the output from the elongatedness calculation (final thinning shown in green), with values of 1.0 and 2.08 for each lesion. Corresponding values of circularity were 0.12, (benign, indicating a more rounded shape) and 0.27.

Considering all manually drawn ROIs; mean values of convexity, were 79.6 ± 11.7% and 93.5 ± 14.5% for malignant and benign lesions respectively (P = 0.001); complexity values were 28.4 ± 14.0 and 17.2 ± 9.3 (P = 0.01); circularity = 0.26 ± 0.08 and 0.22 ± 0.09 (P = 0.147). Corresponding values for automated ROIs were 79.2 ± 11.3% and 94.4 ± 9.5% (convexity, P < 0.001); 32.9 ± 18.1 and 17.0 ± 5.6 (complexity, P < 0.001) and 0.27 ± 0.07 and 0.22 ± 0.08 (circularity, P = 0.064). Elongatedness values were similar in all cases. Complexity values obtained from automated ROIs were significantly different to manual ROI values in malignant lesions only (paired test, P = 0.01).

Conclusions: The semi-automated ROI dramatically reduces the time taken to analyse breast MR data and improves the reproducibility of pixel measurements and morphological descriptors due to the standardisation of the analysis. These results demonstrate the usefulness of shape in discriminating benign and malignant lesions and the efficacy of using semi-automated analysis. Malignant lesions, with higher degrees of irregularity, may be better characterised using semi-automated techniques.

References

[1] CK Kuhl. MRI of breast tumours. *Eur. Radiol.* 2000; 10:46-58. [2] GP Liney et al. Dynamic contrast enhanced MRI in the differentiation of primary breast lesions: the effect of region-of-interest analysis. *J. Magn. Reson. Imag.* 1999; 10:945-949.